

# U. Mickys

Case No. 10

## CLASSICAL DISEASE WITH PROTEAN APPEARANCE

L. Griškevičius  
I. Vengalytė  
R. Stulpinas



VALSTYBINIS  
PATOLOGIJOS  
CENTRAS



UNIVERSITÉ  
DE GENÈVE

SGPath / SSPath  
Société Suisse de Pathologie  
Schweizerische Gesellschaft für Pathologie  
Swiss Society of Pathology



European Association  
for Haematopathology



9th International Course on Bone Marrow Pathology May 7–9 2009 Geneva, Switzerland



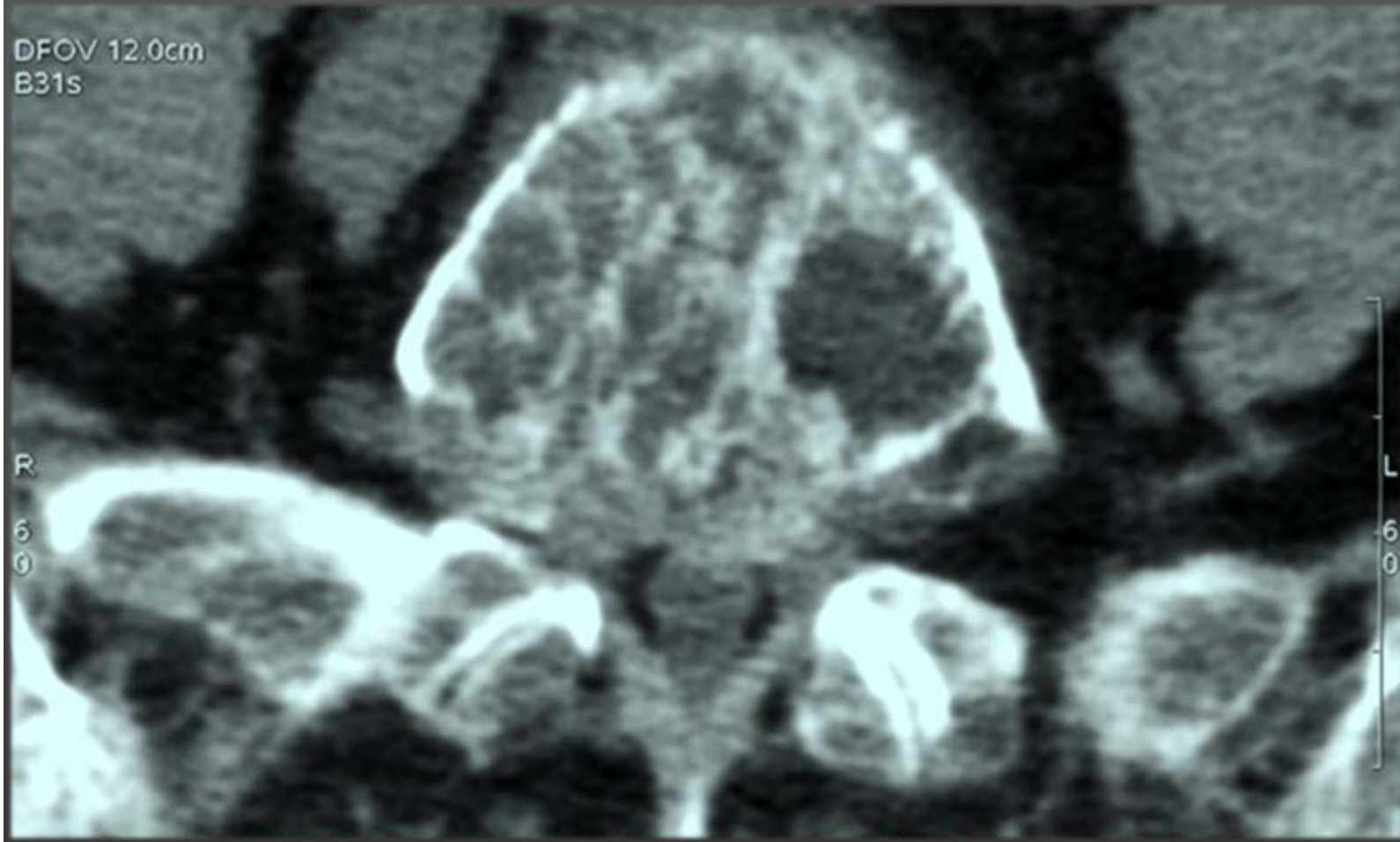# CLINICAL DATA

# Clinical history:

- + 74 year old woman;
- + No history of other disorders, surgery, trauma, drug or any other kind of allergy;
- + Two normal pregnancies;
- + Lower back pain irradiating to both legs lasting for one month;
- + Treatment with NSAIDs had no effect;
- + On OCT 10 2008 fell down, became immobile and was hospitalized due to extensive back pain.

# Physical examination:

- + Palor;
- + Hyperaesthesia in lower extremities;
- + No pathological reflexes found;
- + Lasego symptom about  $70^\circ >$ ;
- + Painful lumboscral part of the spine;
- + Decrease of muscle strength in legs.



## CT scan

Extensive osteoporosis. Compressive deformations (I –II degree) of L2-L4 vertebrae. Left protrusion of L4/5. Focal destructive changes of L3, L5 vertebra bodies.

# Blood test:

Analysis	Result	Standard
WBC (*10e9/l)	7.960	4.0 - 9.0
NEU (*10e9/l)	5.31	2.0-6.93
LYM (*10e9/l)	2.22	1.0-2.5
MON (*10e9/l)	0.31	0.12-0.9
EOS (*10e9/l)	0.09	0.02-0.45
BAS (*10e9/l)	0.02	0-0.09
RBC (*10e12/l)	3.291	Mal.:4.5-5.5, Fem.:4.0-5.1
HgB (g/l)	108.70	Mal.:135-160, Fem.:120-150
Hct (l/l)	0.315	Mal.:0.40-0.48, Fem.:0.36-0.42
MCV (fl)	95.67	82-95
MCH (pg)	33.03	25-35
MCHC (g/l)	345.2	330-348
RDW (%)	14.78	11.6-13.7
Plt (x10e9/l)	207.90	180-320
MPV (fl)	7.60	7.4-10.4

# Biochemical blood test:

Analysis	Result	Standard
Urea (mmol/l)	8,4	2,5-7,5
Creatine (mkmol/l)	92	M:62-115, F:53-97
K (mmol/l)	3,9	3,8-5,3
Na (mmol/l)	134	134-145
Cl (mmol/l)	100	98-107
Glucose(Serum) (mmol/l)	5,3	4,2-6,1
Total protein(g/l)	89.0	66-83
Albumin (%)	38,2 (34 g/L)	53-63
Globulin (%)	61,8	
Alfa 1 (%)	2	2-4,5
Alfa 2 (%)	6,7	6-11
Beta 1 (%)	4	5-8
Beta 2 (%)	2,5	3-5
Gama (%)	46,6	11-19
β2 microglobulin (mcg/ml)	7,83	0,97-2,64

# Blood protein test:

Analysis	Result	Standart
B2 microglobulin (mg/L)	7,83	0,97-2,64
Immunoglobulin A (g/L)	0,49	Mal.: 0,7-3,7 Fem.: 0,88-4,1
Immunoglobulin G (g/L)	49,36	7,0-16,0
Immunoglobulin M (g/L)	0,16	Mal.: 0,40-2,40 Fem.: 0,34-2,10

Paraprotein – IgG lambda



# Serum protein electrophoresis:

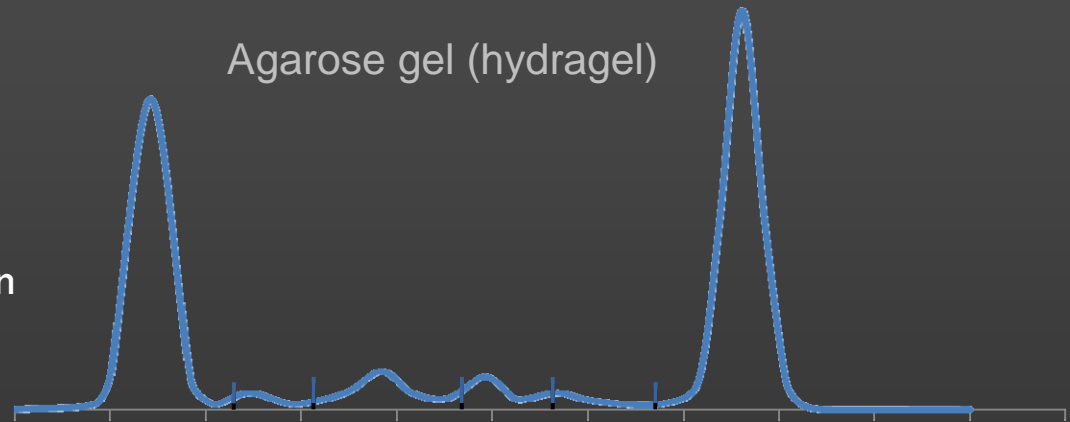
Total protein = 89.0 g/l

A/G = 0.62

Globulins 61.8%

Comments:

monocline in gamma fraction



Fraction	%	g/l	Norm %	g/l
Albumin	38.2	34.0	60-70	43-51
Alpha 1	2.0	1.8	1.4-2.7	1-3
Alpha 2	6.7	6.0	7-11	5-8
Beta 1	4.0	3.6	6-9	4-6
Beta 2	2.5	2.2	2-5	1-4
Gamma	46.6	41.4	8-16	6-12

# Bone marrow aspiration:

Type of cell	Normal range, %	BM aspirate	BM imprint	Comment
Lymphoid cells and lymphocytes	10,0-13,0	25	18	Pancytopenia, significantly increased amount of plasma cells, representing different stage of maturation, partialy with irregular forms. Decreased granulopoesis. Single megacariocytes. Anisocytosis. Rouleux formation of RBC.
Blasts	0,0-3,0	0	1	
Myelocyte	3,0-12,0	6	6	
Metamyelocyte	8,0-14,0	3	4	
Promonocyte	0,2-0,5	0	0	
Monocyte	1,0-2,0	4,5	0	
Plasma cells	0,4-1,6	12	38	
Megakaryocytes	38,8-150	11,4	Singles	

# Clinical diagnosis:

- + Multiple myeloma IgG lambda;
- + ISS stage III:
  - + Albumin 34 g/l;
  - +  $\beta$  2 microglobulin - 7,8 mcg/l;
- + Compressive deformations of L2 - L4 vertebrae.



TREATMENT

# Response to given treatment:

- + 6 courses of Melphalane + Prednisolone administered.
- + Reduced back pain;
- + Starting to walk (minor improvement);
- + Reduction of M protein by 68% (partial remission achieved);
- + Treatment with MP will be continued until plateau phase is reached (stable M protein level for 2 months).

# Tests after treatment:

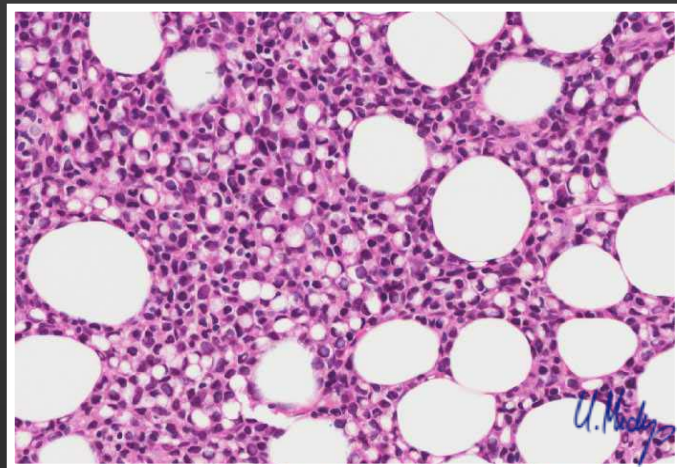
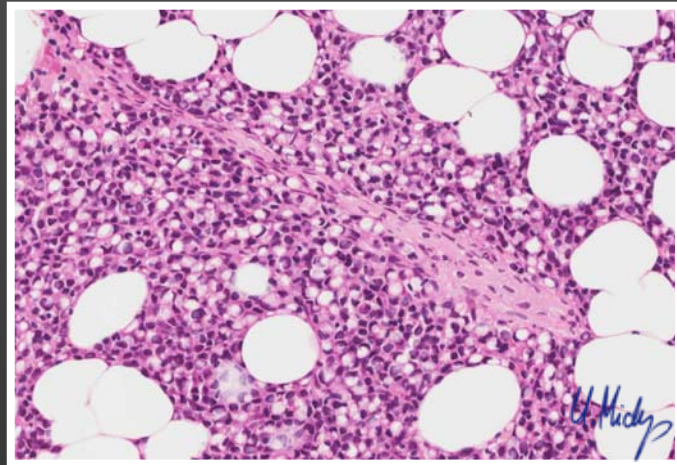
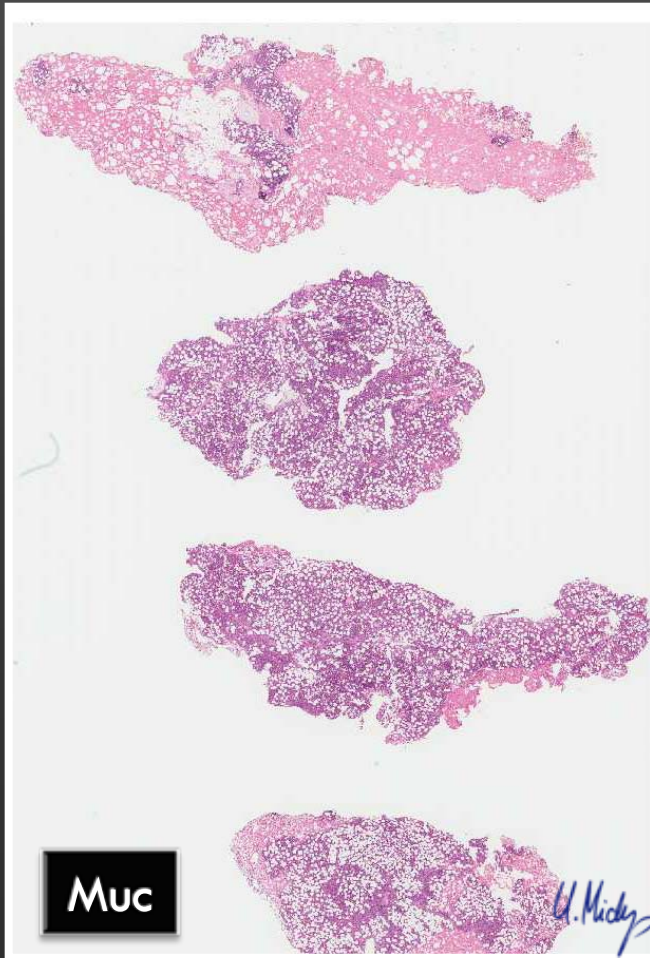
Analysis	Result post	Result pre	Standard
Immunoglobulin A (g/L)	0,29	0,49	Mal.: 0,7-3,7 Fem.: 0,88-4,1
Immunoglobulin G (g/L)	26,55	49,36	7,0-16,0
Immunoglobulin M (g/L)	0,28	0,16	Mal.: 0,40-2,40 Fem.: 0,34-2,10
Total protein (g/l)	77	89	66-83
$\beta$ 2 microglobulin (mg/L)	3,1	7,83	0,97-2,64
Alfa 1 (%)	2,2	2	2-4,5
Alfa 2 (%)	9	6,7	6-11
Beta 1 (%)	5,3	4	5-8
Beta 2 (%)	2,5	2,5	3-5
Gama (%)	20,7	46	11-19
M gradient (g/l)	13,7	41	



# HISTOLOGY

# Histology

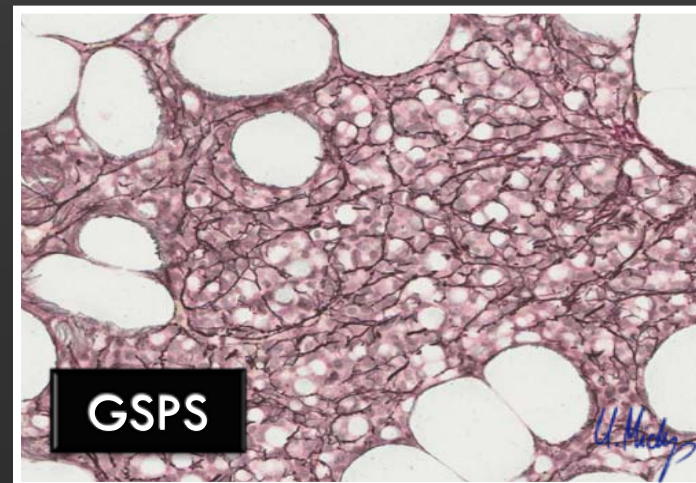
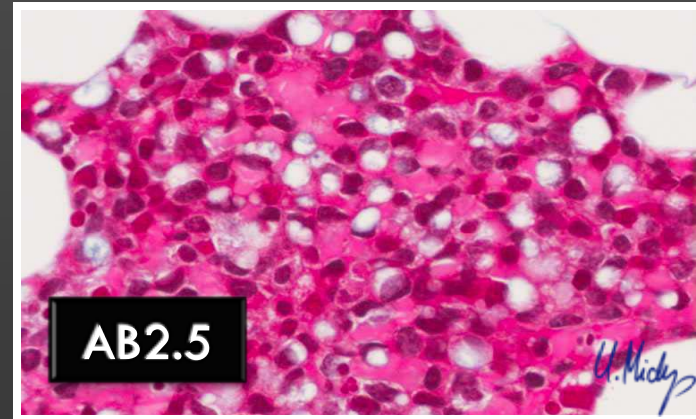
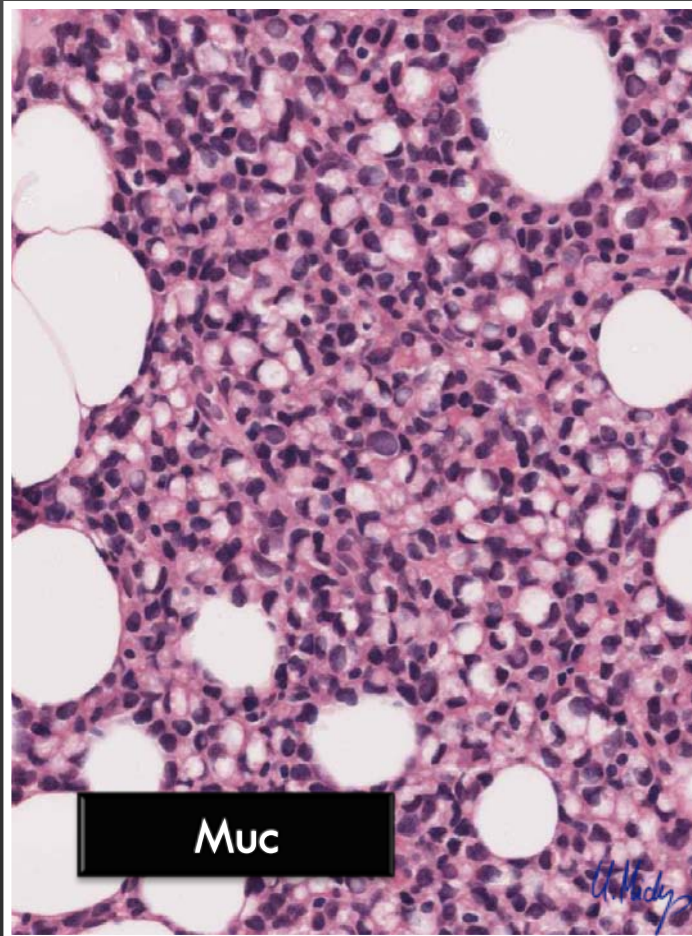
Part 1:





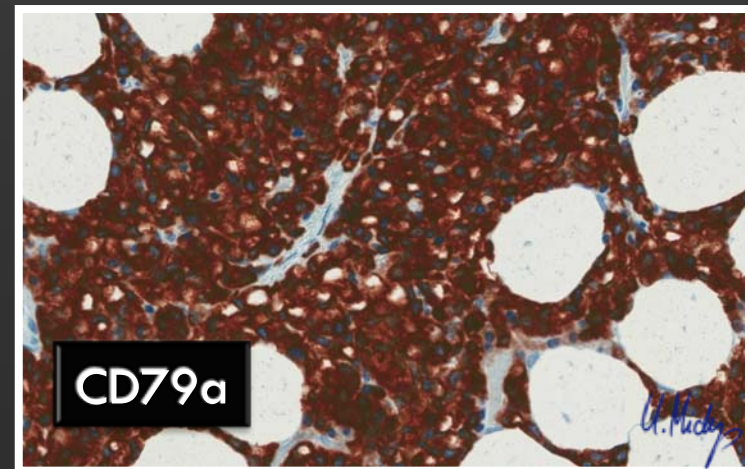
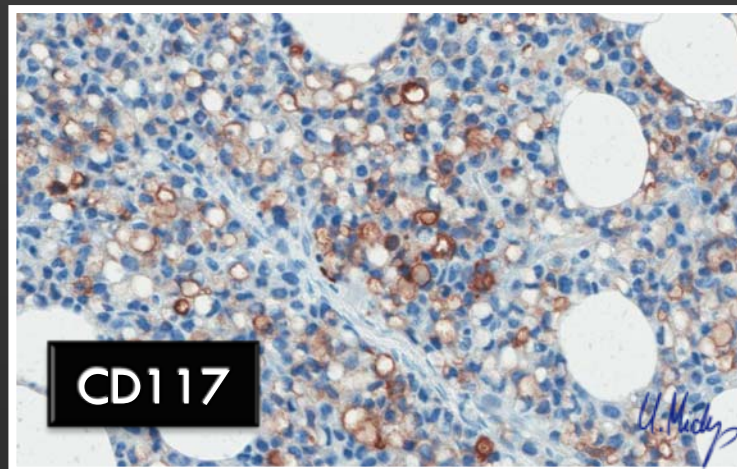
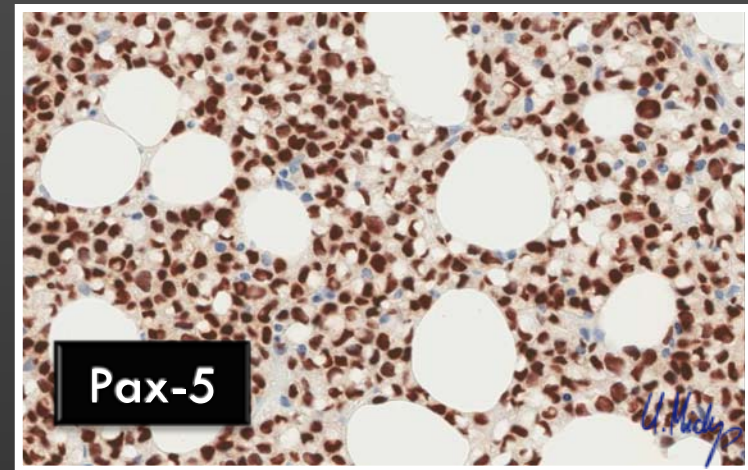
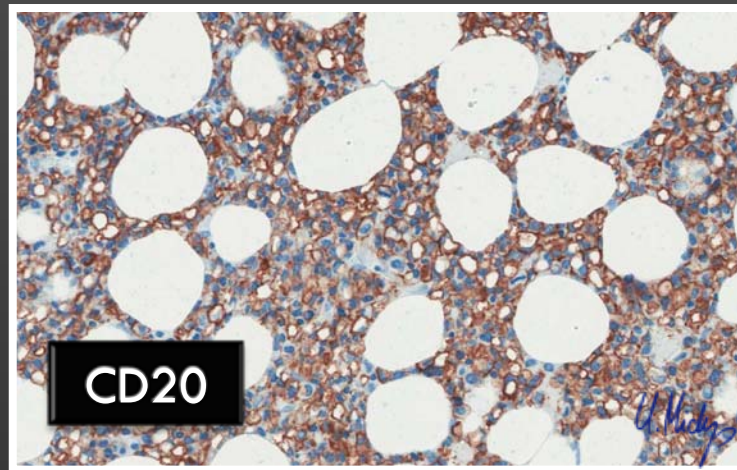
# Histology

Part 2:



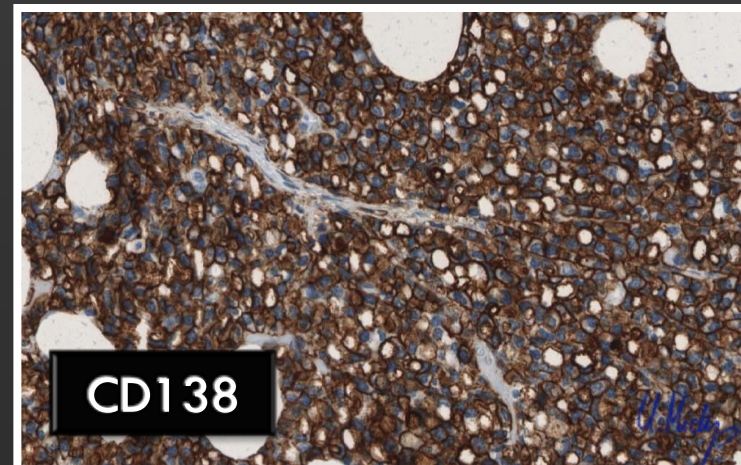
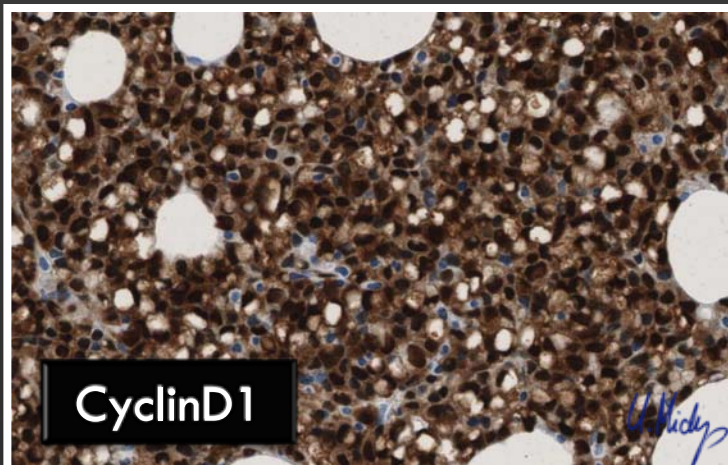
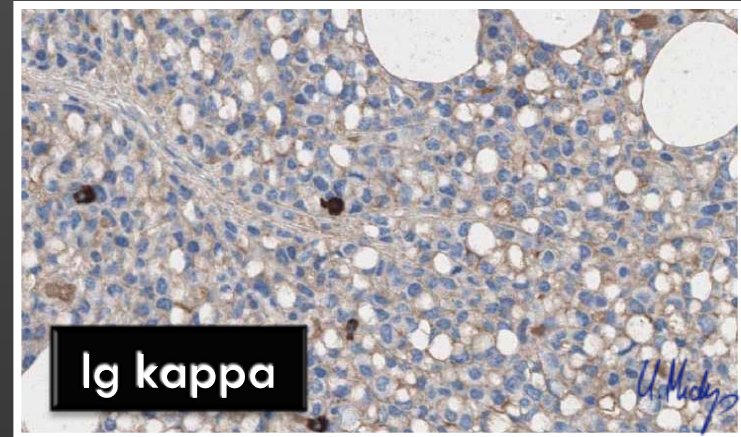
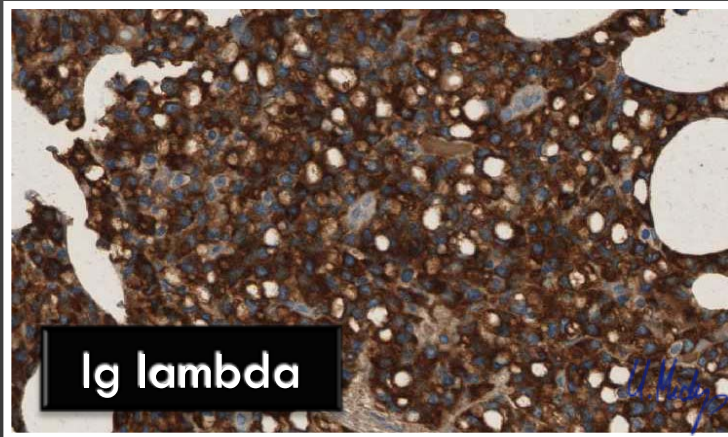
# Histology

## Part 3:



# Histology

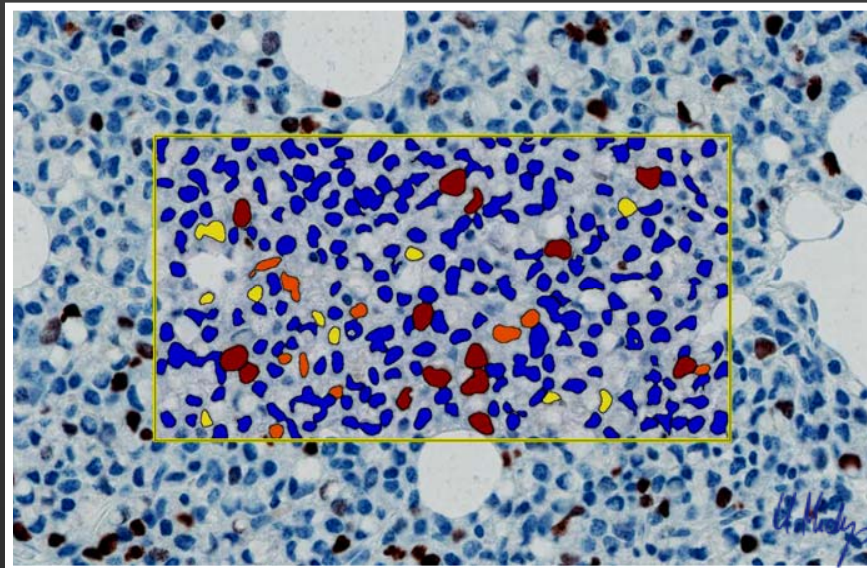
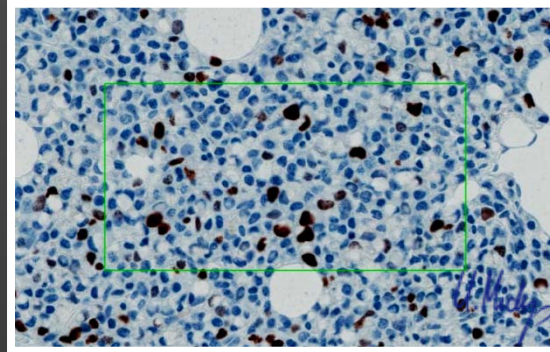
Part 4:



# Histology

## Part 5:

Ki67 14,7%  
(Apperio  
Nuclear 9.0)



Layers: Layer 1, Result 2

Layer Attributes

Percent Positive Nuclei	14.7186
Intensity Score	2
(3+) Percent Nuclei	6.06061
(2+) Percent Nuclei	4.329
(1+) Percent Nuclei	4.329
(0+) Percent Nuclei	85.2814
Average Positive Intensity	170.059
Average Negative Intensity	238.68
(3+) Nuclei	14
(2+) Nuclei	10
(1+) Nuclei	10
(0+) Nuclei	197
Total Nuclei	231
Average Nuclear RGB Intensity	131.247
Average Nuclear Size (Pixels)	683.017
Average Nuclear Size (um <sup>2</sup> )	42.7227
Area of Analysis (Pixels)	499364
Area of Analysis (mm <sup>2</sup> )	3.1235223193639996
*** Algorithm Inputs ***	
Algorithm	Nuclear v9
Version	9.1
View Width	1000
View Height	1000
Overlap Size	100
Image Zoom	1
Classifier	None
Class List	
Classifier	0

# Trephine biopsy

OCT 21 2008:

- + Fixation: Buffered 10% formalin
- + Decalcification: „Mielodec“ (Bio-optica): hydrochloric acid
- + Processed ordinary and parafin embedded.
- + Histochemical stains:
  - + AB2.5/mucikarmin negative
  - + Methyl Green Pyronin: negative
- + IF:
  - + IgG (+) 80%
  - + IgA(-)
- + Flow cytometry: Not done
- + Molecular analysis: Not done
- + Cytogenetics: Not done
- + IH:
  - + PanCK/CAM5.2(-),
  - + CD138(+++) 100%
  - + CD20(++) 100%
  - + LCA(+++) 100%
  - + CD79a(+++) 100%
  - + PAX5(++) 100%
  - + Ig lambda(+++)100% and Ig kappa(-)
  - + CyclinD1(+++)100%
  - + CD117(+/++) 30%
  - + EMA(+/++) 10%
  - + IgM/IgD(-),
  - + CD56(-).
  - + Ki67 proliferative activity ~15%

# Plasma cell cytological variants

- + Conventional (Marchalko cells)
- + Flaming cells (IgA)
- + Mott, morular, grape cells
- + Thesauocytes
- + With crystalline deposits
- + With Russell and Dutcher bodies
- + Cleaved, multilobated and monocytoid cells/  
polymorphous
- + Pleomorphic
- + Blastic
- + **Signet ring**
- + Small
- + Histiocytoid
- + Clear
- + Spindle
- + Oncocytic

# Myeloma: IH variations

## + CyclinD1+ increased

~ CD20+ expression; lymphoplasmacytic morphology;  
amount of plasma cells; better survival;

Cook JR, Hsi ED, Worley S, Tubbs RR, Hussein M.

Immunohistochemical analysis identifies two cyclin D1+ subsets of plasma cell myeloma, each associated with favorable survival. *Am J Clin Pathol.* 2006 Apr;125(4):615-24.

## + CD138 loss

~ Complicated IH diagnostics

Svrcek M, Meignin V, Brière J, Quillard J, Mariette X, Audouin J, Janin A.

Multiple myeloma with loss of CD138 expression in two rare metastatic localizations, peritoneum and skin. *Histopathology.* 2007 Jun;50(7):952-4.

## + CD117+

~ Better prognosis?

The prevalence and clinical implications of c-kit expression in plasma cell myeloma.

Pruneri G, Ponzoni M, Ferreri AJ, Freschi M, Tresoldi M, Baldini L, Mattioli M, Agnelli L, Govi S, Mancuso P, Agazzi A, Bertolini F, Peccatori J, Bosari S, Gianelli U, Viale G, Neri A. *Histopathology.* 2006 Apr;48(5):529-35.

CD117 (c-kit) is aberrantly expressed in a subset of MGUS and multiple myeloma with unexpectedly good prognosis.

Bataille R, Pellat-Deceunynck C, Robillard N, Avet-Loiseau H, Harousseau JL, Moreau P. *Leuk Res.* 2008 Mar;32(3):379-82. Epub 2007 Sep 4.

# Myeloma: IH variations

## + Pax-5+

Lin P, Mahdavy M, Zhan F, Zhang HZ, Katz RL, Shaughnessy JD Expression of PAX5 in CD20-positive multiple myeloma assessed by immunohistochemistry and oligonucleotide microarray. .  
Mod Pathol. 2004 Oct;17(10):1217-22..



# PubMed searches,

MAY 05 2009:

- + Signet ring (cell) myeloma  
/plasmacytoma ~7 records
- + CyclinD1 (positive) myeloma ~13 records
- + Signet ring (cell) lymphoma ~61 records
- + Signet ring cell myeloma  
CyclinD1+ **No records**

Earliest detected: Dorfman RF. Multiple myeloma showing signet-ring cell change. *Histopathology*. 1991 Jun;18(6):577-8.

Case No. 10

## CLASSICAL DISEASE WITH PROTEAN APPEARANCE

### + PROPOSED DIAGNOSIS:

IgG+ plasma cell myeloma (signet ring cell variant)  
with CyclinD1 positivity.



"Clear your mind must be if you are to discover  
the real villains behind the plot..."

*Yoda, the Jedi Master*